

Supplemental Figure 1

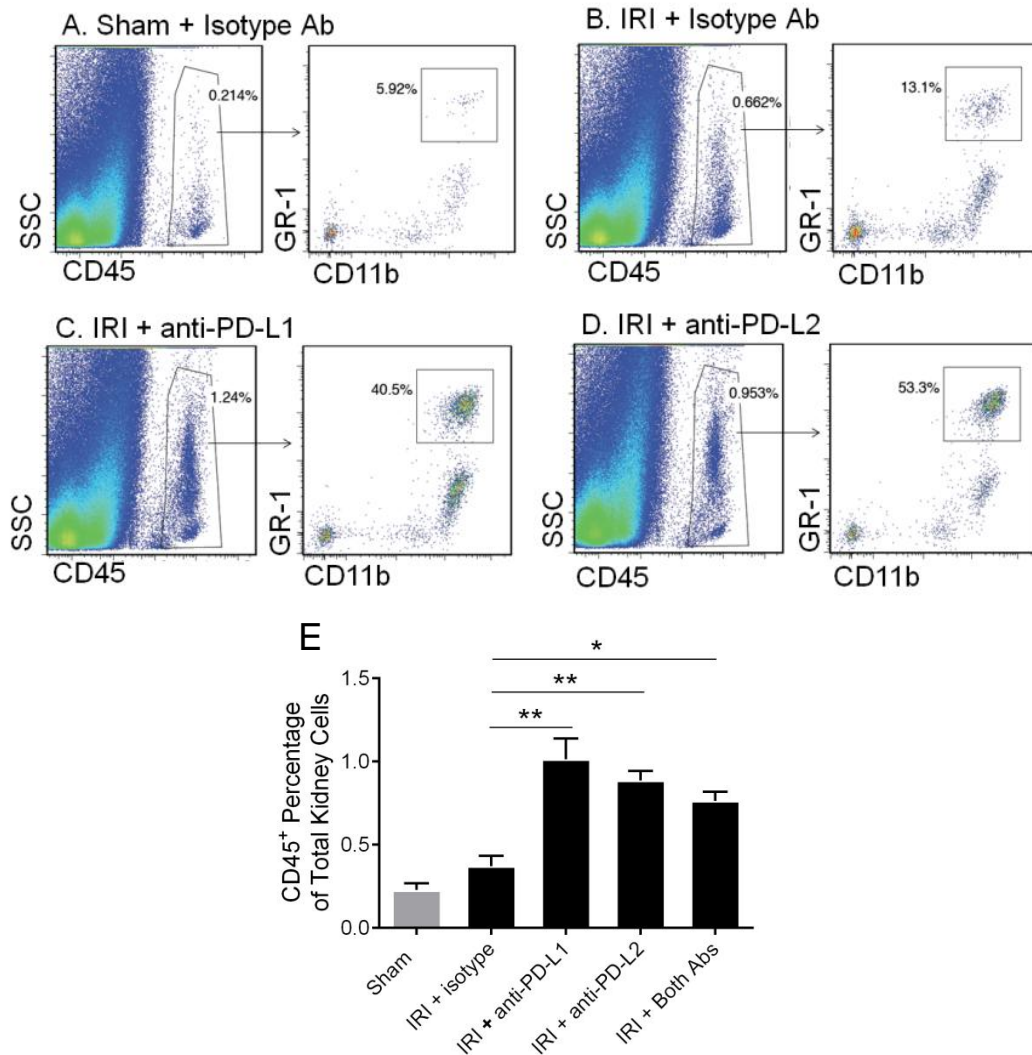


Figure S1. Renal leukocyte accumulation is exacerbated by PD-1 ligand blockade. Naïve WT mice were treated with isotype control antibodies, anti-PD-L1 or anti-PD-L2. After 24 hours, sham or bilateral kidney IR surgery was performed. At 24 hours of reperfusion kidneys were harvested and digested with collagenase and cells were labeled for flow cytometry as described in the Materials and Methods section. The left side dot plots show the total leukocyte percentage (CD45+) in the kidneys from each group and the right side plots show the percentage of CD11b+ and GR-1high innate leukocytes (A-D). Dead cells (7-AAD+) were excluded from analysis (not depicted). N=7-11 per group, pooled from 3 independent experiments. Data are presented as mean + SEM, * denotes $P < 0.05$; ** denotes $P < 0.01$ (E).

Supplemental Figure 2

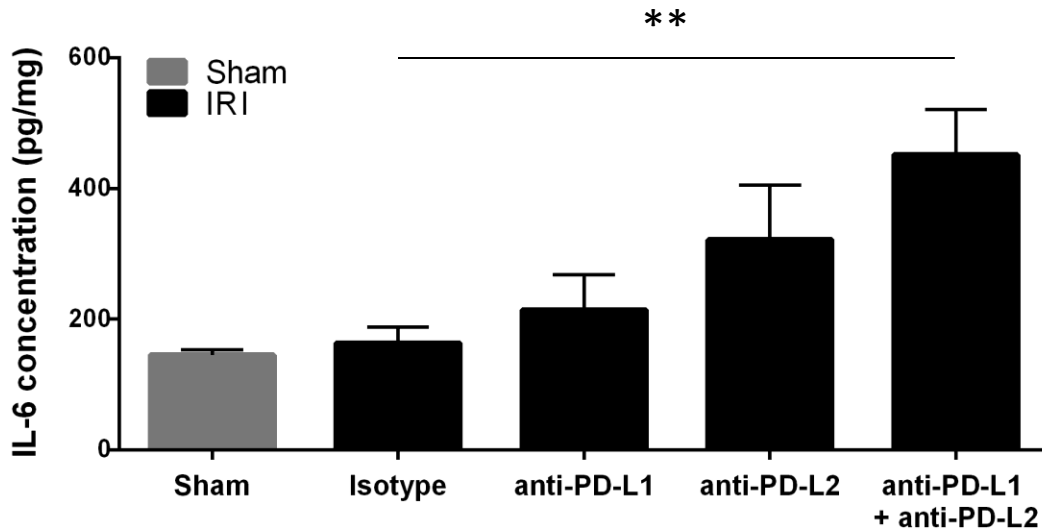


Figure S2. Combined PD-1 ligand blockade increases renal IL-6 protein levels after ischemia. Naïve WT mice were treated with isotype control antibodies, anti-PD-L1 or anti-PD-L2 or the combination of both blocking antibodies. After 24 hours, sham or bilateral kidney IR surgery was performed. At 24 hours of reperfusion kidneys were homogenized and subjected to IL-6 ELISA as described in the Materials and Methods section. Data are presented as mean + SEM, ** denotes $P < 0.01$. $N = 5$ for sham, 9-11 for each IRI group, pooled from 3 independent experiments.

Supplemental Figure 3

A. IRI + Tregs + Isotype

B. IRI + Tregs + anti-PD-L1

C. IRI + Tregs + anti-PD-L2

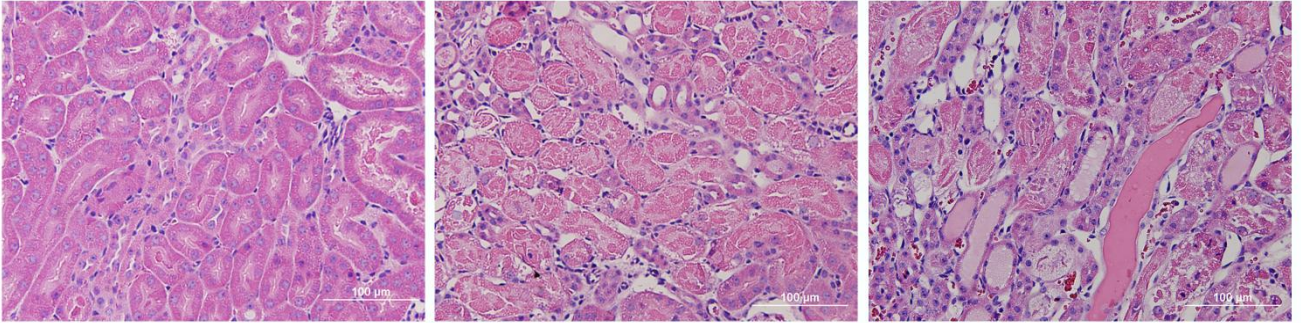


Figure S3. PD-1 ligand blocking antibodies negate the protective effect of regulatory T cell adoptive transfer in kidney IRI. Naïve WT mice were treated with isotype control antibodies, anti-PD-L1 or anti-PD-L2. Six hours later mice were administered either 100,000 freshly-isolated WT Tregs in normal saline. After 18 hours mild kidney IR surgery (24 min ischemia) was performed, and the kidneys were allowed to reperfuse for 24 hours. To assess renal tissue injury ATN was assessed using H&E stained kidney sections.